

A Classification System for Postburn Mentosternal Contractures

Ifeanyichukwu Igwilo Onah, FWACS

Hypothesis: Postburn mentosternal contractures can be clinically classified into 4 major groups based on the location of the contracting band(s) and extent of flexion or extension away from the anatomical position of the neck and jaws. Each group can be further subclassified depending on the width of the contracting segment(s) and availability of surrounding supple skin.

Design: Case series.

Setting: Nigerian subregional apex hospital specializing in plastic surgery, orthopedic surgery, and traumatology.

Patients: A consecutive sample of 41 patients with postburn mentosternal contractures who underwent surgery between 1997 and 2002 and 4 patients who had not yet had surgery, seen between January and March 2003. Data were obtained from operative records, photo-

graphic records, and interview of teams who treated the patients. During data collection, a classification system was devised in which mild, moderate, and severe anteriorly located contractures were designated types 1, 2, and 3, and posteriorly located contractures were considered type 4. Subtypes a through d were included to denote characteristics affecting reconstruction.

Results: The classification system was successfully used to classify postburn mentosternal contractures as a guide to management. Sufficient data were available to classify 32 of the 45 patients. The observers were not blinded.

Conclusion: The classification system is useful in describing severity and guiding reconstructive options, but further study is required before it is used in choice of airway management for anesthesia.

Arch Surg. 2005;140:671-675

POSTBURN MENTOSTERNAL contractures are frequently seen in the plastic surgical service of the National Orthopaedic Hospital, Enugu, Nigeria. Between 1997 and 2002, 41 patients with mentosternal contractures underwent surgery there; 14 of these had associated upper limb contractures. Not only is this condition unsightly (thereby causing the patient great social embarrassment), but it limits full range of neck flexion and extension. This affects intubation, and therefore these patients must have the postburn contracture released before other procedures are performed so as to ensure airway control.¹ All but 1 of these patients had the neck contracture released before other contractures were released. Difficult decisions with regard to anesthesia are frequently met in this situation.² Most of the patients have the contracting band divided before intubation, as intubation would otherwise have proved impracticable, but some can be intubated without much difficulty even without prior division of the contracture.

In addition to anesthetic decisions, virtually the whole range of the plastic surgeon's reconstructive options is needed for the treatment of this condition. I have so far been directly involved in the treatment of 7 of these patients. I found that a classification system would be helpful in determining the best approach to reconstruction in each case. Kirschbaum³ in 1958 reported Spina's classification of neck contractures into central, lateral, or complete. Achauer⁴ in 1991 classified anterior neck contractures into mild, moderate, extensive, and severe depending on what fraction of the anterior part of the neck is involved in the contracting band. I used my own observations and involvement in the treatment of patients with mature scars affecting mentosternal excursion to develop the classification system described in this article.

METHODS

The classification system for postburn mentosternal contractures was based on a consecu-

Author Affiliations:

Department of Burns, Plastic and Reconstructive Surgery, National Orthopaedic Hospital, Enugu, Nigeria.

tive sample of 41 patients who underwent reconstructive surgery between 1997 and 2002 and 4 patients who had not yet had surgery, seen by me between January and March 2003. Excluded from this classification were patients who additionally had cervical spondylosis; intraoral, oropharyngeal, or nasopharyngeal masses; obesity; achondroplasia; acromegaly; Marfan syndrome; Pierre Robin sequence; and/or other conditions in which difficult intubation may be anticipated³ or neck flexion or extension may be impaired.

RESULTS

CLASSIFICATION SYSTEM

The classification system includes major numeric categories of 1 to 4, which encompass position, severity, and likely problems. Subgroups within each numeric category are used to designate the width of the contracture, which has implications for the options available for

reconstruction. The numeric category is based on the extent of flexion or extension by the contracted neck and the anatomical position of the neck. The ability of the patient in the erect position to reach or extend beyond the anatomical position of the neck and jaws (**Figure 1**) helps to determine placement in category 1, 2, or 3, which are all anteriorly located contractures (mild, moderate, or severe, respectively). Type 4 is used for posteriorly located contractures. **Table 1** shows the category distribution of the 41 patients studied retrospectively. The patients seen prospectively included 1 with type 1a contracture, 1 with type 4a, and 2 with type 4c.

TYPE 1

Type 1 is a mild anterior contracture. The patient is able to flex the neck and bring the neck and jaws to the anatomical position while erect. In addition, limited exten-

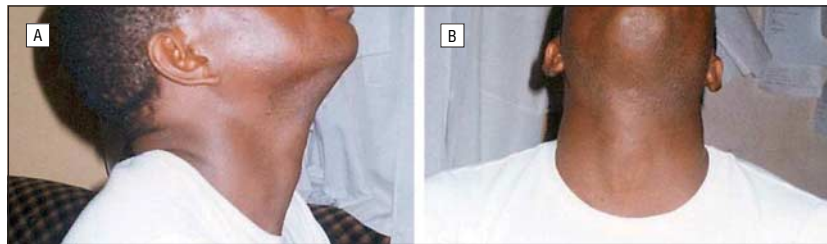


Figure 1. A normal subject in full extension. This is the norm with which the anterior contractures are compared.

Table 1. Types of Postburn Mentosternal Contractures Operated on in the National Orthopaedic Hospital, Enugu, Nigeria, 1997 to 2002

Contracture Subtype	No. of Patients by Year						Total
	1997	1998	1999	2000	2001	2002	
1a	0	0	0	0	0	0	0
1b	0	0	1	0	0	0	1
1c	0	0	0	0	0	1	1
2a	0	1	0	0	0	1	2
2b	0	0	0	0	0	0	0
2c	0	0	0	0	0	0	0
3a	1	0	0	0	0	0	1
3b	1	5	2	0	6	8	22
4a	0	0	0	0	0	0	0
4b	0	0	1	0	0	0	1
4c	0	0	0	0	0	0	0
Not determined	0	5	1	2	4	1	13
Total	2	11	5	2	10	11	41

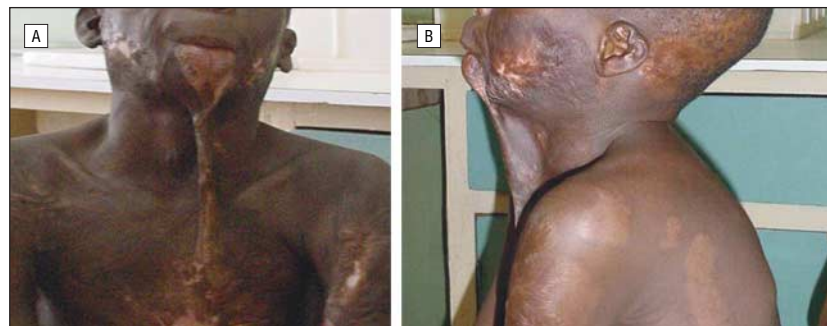

Figure 2. Type 1a contracture.

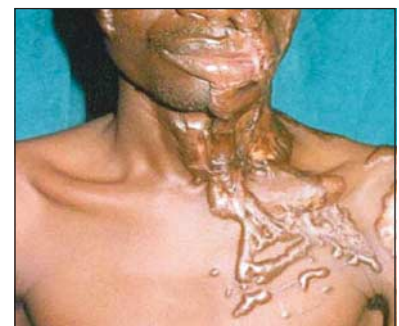

Figure 3. Type 1b contracture.

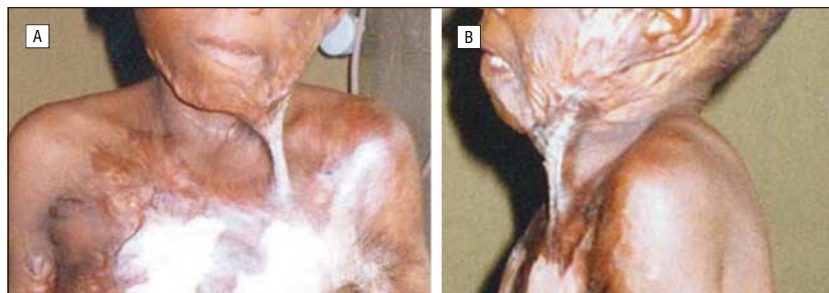

Figure 4. Type 2a contracture.

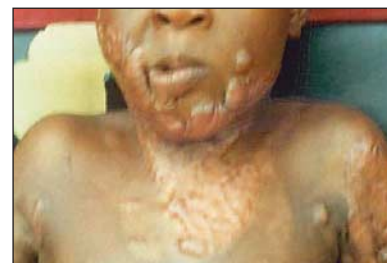

Figure 5. Type 2b contracture.

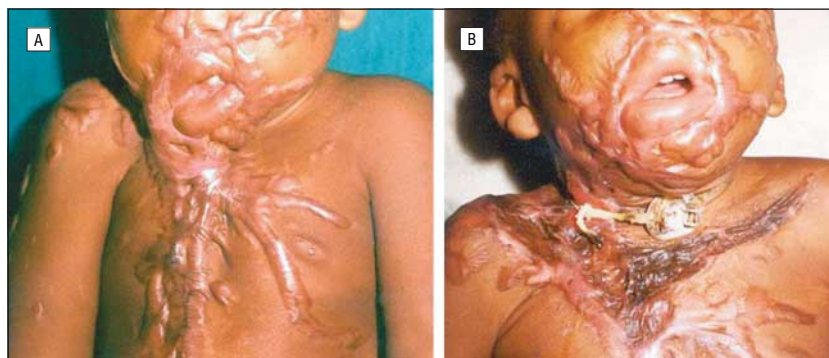

Figure 6. Type 3a contracture.

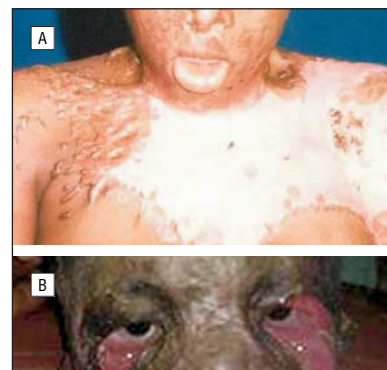

Figure 7. Type 3b contracture. A, Typical appearance of a patient with a type 3b contracture. B, Typical appearance of the eyes in another patient.

sion away from the anatomical position is possible; there is an inability to place an object located on the ceiling (180° to the erect patient, or 90° to the horizontal plane in the sitting patient) in the center of the visual field.

In type 1a (**Figure 2**), the mature contracting band is narrow, not exceeding 2 fingers' breadth (ie, the patient's own). Supple adjacent neck skin is available on either side of the band for local transposition flaps. One patient in the prospective group was in this category.

In type 1b (**Figure 3**), the contracting band is broad; however, there is sufficient adjacent supple neck skin to cover the reconstructed defect after excision of the contracting segment. One patient in the retrospective group was in this category.

In type 1c, the contracting segment is broad, involving most or all of the anterior part of the neck, and/or there are a number of contracting bands in the neck including the mentosternal band. As a result, there is insufficient adjacent supple neck skin to cover the reconstructed defect after excision of the contracting segment. One patient in the retrospective group was in this category. He did not request surgery for it, and he had uneventful intubation and subsequent surgery for associated axillary contractures.

TYPE 2

Type 2 is a moderate anterior contracture. Patients with this type of contracture are able to flex the neck and bring the neck and jaws to the anatomical position while erect. Attempts at extension away from the anatomical position result in a significant pull at the (uninvolved) lower lip.

In type 2a (**Figure 4**), the width of the mature contracting band is narrow, not exceeding 2 fingers' breadth. Supple adjacent neck skin is available on both sides of the contracting band for local transposition flaps. Two such patients were operated on in the retrospective series.

In type 2b (**Figure 5**), the contracting band is broad; however, there is sufficient adjacent supple neck skin to cover the reconstructed defect after excision of the contracting segment.

In type 2c, the contracting segment is broad, involving most or all of the anterior neck skin, and/or there are a number of contracting bands in the neck including the mentosternal band. As a result, there is insufficient adjacent supple neck skin to cover the reconstructed defect after excision of the contracting segment.

TYPE 3

Type 3 is a severe anterior mentosternal contracture. The patient's neck is contracted in the flexed position and the chin (and less frequently the lower lip) is occasionally restrained down to the anterior trunk. The patient is unable to reach anatomical position of the neck and jaws. In the attempt, the superior limbus of the unaffected eye is covered and the inferior limbus of the unaffected eye is clearly seen. The attempt also usually pulls on the (uninvolved) lower lip. Twenty-three such patients were operated on in the years under review.

In type 3a (**Figure 6**), the contractural segment has enough supple neck skin to cover the reconstructed defect. One such patient was included in the retrospective group.

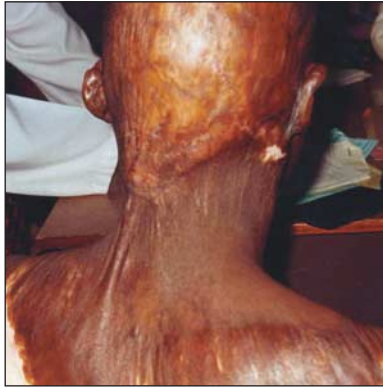

Figure 8. Type 4a contracture.

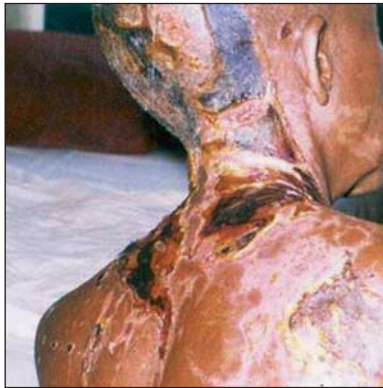

Figure 9. Type 4b contracture in an elderly woman burned by a corrosive substance.

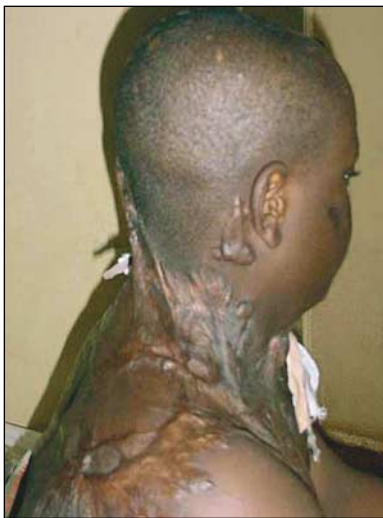

Figure 10. Type 4c contracture.

In type 3b (**Figure 7**), the contractural segment has insufficient supple neck skin to cover the reconstructed defect. Twenty-two (54%) of those in the review fall into this group.

TYPE 4

Type 4 is a posteriorly located contracture. The contracting band at the back of the neck prevents full neck flexion and may hold the neck in some degree of extension (**Figure 8**). It is not as common as types 1 to 3, but it occurs after full-thickness burns to the back of the neck,

particularly from corrosives, in elderly people (**Figure 9**). In our practice, all but 1 have been victims of assault with corrosives. Only 1 such patient was operated on in the years under review, but 3 presented to the hospital in 2003.

In type 4a (**Figure 8**), posterior contracture occurs alone as a result of a narrow contracting band, not exceeding 2 fingers' breadth. Supple adjacent neck skin is available on either side for local transposition flaps.

In type 4b, posterior contracture occurs alone as a result of a single broad band or multiple bands. Supple adjacent neck skin is not available for local transposition flaps.

In type 4c (**Figure 10**), posterior contracture occurs in association with anterior neck contracture.

COMMENT

INFLUENCE OF CLASSIFICATION ON ANTICIPATED PROBLEMS IN MANAGEMENT

Difficulty with intubation can be anticipated when the distance between the chin and the thyroid prominence is less than 6 cm in the adult.⁵ In type 3 this distance is shortened, and division of the contracture preceded intubation in all such patients in the years under review. On 2 occasions a tracheotomy was needed.

In type 2, fiberoptic-assisted intubation may be done^{2,5} and is the recommended mode for airway management in these patients; however, I believe blind intubation can occasionally be done successfully in this type of contracture when fiberoptic assistance is unavailable. If intubation fails, the contracting band should be divided as in type 3.

In types 1 and 4a and b, undue problems with intubation are not expected. In type 3 patients who were reclassified to type 1 after surgical release, this has been the experience at our institution (apart from those within the exclusion criteria).

In type 1, the contracted tissues in front of the neck are the skin and subcutis. Dealing with them alone usually enables the surgeon to achieve a satisfactory release. Type 4a is expected to behave similarly. However, in type 3 the strap muscles are frequently contracted also. They will need to be addressed if a full release is to be achieved. I treated 1 such patient with a type 3b contracture, to extend the neck prior to split-skin graft. Distortions of the cervical spine and tracheal alterations affecting respiration are most probable here.

INFLUENCE ON SURGICAL OPTIONS

In types 1a, 2a, and 4a, Z-plasty (or some modification of it) is an excellent option. All patients with types 1a and 2a contractures were treated with Z-plasty. In addition, in these categories there is usually time to address another associated contracture in the same sitting without undue prolongation of the operating time.

In types 1b, 2b, 3a, and 4b, local flaps can be used with or without the addition of skin grafts to cover the secondary defect⁶ (as in **Figure 6**). Split-skin grafts were used in the 2 cases of types 1b and 4b operated on in the years un-

Table 2. Surgical Procedures Performed for Reconstruction of Postburn Mentosternal Contractures by Contracture Subtype

Subtype	No. of Cases	Procedures
1a	1	Z-plasty
1b	1	SSG
1c	1	0
2a	2	Z-plasty (2)
2b	0	NA
2c	0	NA
3a	1	Local flap + SSG
3b	22	SSG (20); regional flap + SSG (2)
4a	1	NA
4b	1	SSG
4c	2	Distant flap (1)

Abbreviations: NA, not applicable; SSG, split-skin graft.

der review. Expanded skin flaps may also be used in these cases.⁷ In types 1c, 2c, 3b, and 4c, sheets of skin grafts, expanded flaps, and regional and distant flaps have been used extensively, including free flaps.⁷⁻⁹ In the years under review, type 3b reconstructions were managed with split-skin grafts exclusively in 20 cases and with flaps and grafts in 2 cases (**Table 2**). Three patients underwent staged release at a week's interval before skin grafts were applied. Eight had repeated grafting after contraction of the bed. In the patient in Figure 10 (type 4c), who presented in 2003, I used an island trapezius myocutaneous flap on the left side. Subsequent intubation for surgery on the ear deformity at a later date was uneventful. Subsequent surgeries are planned for the right side, as is debulking of the flap.

INFLUENCE ON AIMS OF SURGERY

The classification is also expected to influence the aim of the surgery. In contracture surgery, the purpose is both functional and aesthetic correction, preferably in a single staged procedure.⁷ The surgical procedures reviewed endeavored to downgrade contractures of types 4c, 3, and 2 to 1 or normal full range of movement. Types 4a and b and 1 should be corrected to normal full range of movement. I believe the surgery should be regarded as failed or unsatisfactory if patients with anterior contractures after surgery are unable to reach type 1. Staging of surgery may be needed in types 3b and 4c to achieve a satisfactory result. Eight of those with type 3b contrac-

tures had more than one release surgery done. I expect the results of types 4a and 1a surgeries to be the most consistently rewarding.

Accepted for Publication: June 2, 2004.

Correspondence: Ifeanyichukwu Igwilo Onah, FWACS, National Orthopaedic Hospital, PMB 1294, Enugu, 400001, Enugu State, Nigeria (anyionah@yahoo.com).

Previous Presentation: This article was presented at the 43rd Scientific Conference of the West African College of Surgeons; January 27, 2003; Abuja, Nigeria.

Acknowledgment: P. B. Olaitan, MD, and B. C. Jiburum, MD, FWACS, encouraged me to publish this work. Figures 6 and 9 are published with Dr Jiburum's kind permission. I also acknowledge I. S. Ogbonnaya, MD, FWACS, with whom I worked as a senior registrar before my appointment as consultant plastic surgeon; the freedom to treat a few of these patients was granted by him. Figure 2 was photographed with his permission. He and M. C. Odiakosa, MD, made useful comments on some aspects of the work. Without the assistance of the Medical Illustration Unit, National Orthopaedic Hospital, Enugu, Nigeria, no photographs would have been available for this article. I also gratefully acknowledge the assistance of Iyke Ifeanacho in computer work.

REFERENCES

- MacLennan SE, Corcoran JF, Neale HW. Tissue expansion in head and neck burn reconstruction. *Clin Plast Surg*. 2000;27:121-132.
- Ademola SA. Release of contractures. In: Oluwatosin OM, ed. *Methods of Repair*. 4th ed. Ibadan, Nigeria: Shalom Productions; 2003:80-94.
- Kirschbaum S. Mentosternal contracture: preferred treatment by acromial (in charretera) flap. *Plast Reconstr Surg*. 1958;21:131-138. Cited by: Aranmolate S, Attah AA. Bilobed flap in the release of post burn mentosternal contracture. *Plast Reconstr Surg*. 1989;83:356-361.
- Achauer BM. Neck reconstruction. In: Achauer BM, ed. *Burn Reconstruction*. New York, NY: Thieme Medical Publishers; 1991:79-86.
- Atkinson RS, Rushman GB, Davies NJH. Tracheal intubation. In: Atkinson RS, Rushman GB, Davies NJH, eds. *Lee's Synopsis of Anaesthesia*. 11th ed. Oxford, England: Butterworth-Heinemann; 1993:222-228.
- Aranmolate S, Attah AA. Bilobed flap in the release of postburn mentosternal contracture. *Plast Reconstr Surg*. 1989;83:356-361.
- Abdel-Razek EM. Expanded supraclavicular artery island flap for post-burn neck reconstruction. *Ann Burns Fire Disasters*. 1999;12:107-115.
- Kadry M, Hassan A, Tewfik O, Ismail M. Recent fasciocutaneous flaps for repair of post-burn neck, axillary and elbow contractures. *Ann Burns Fire Disasters*. 1989; 2:89-97.
- Badran HA. Lateral intercostal microvascular flap for release of neck scar. In: Strauch B, Vasconez LO, Hall-Findlay EJ, eds. *Grabb's Encyclopaedia of Flaps*. 2nd ed. Philadelphia, Pa: Lippincott-Raven; 1988:481-484.